

GE Healthcare

# Tissue Synchronization Imaging (TSI) in Clinical Practice

Ole Breithardt, M.D.

Susan Floer, BS, RDCS

Hans-Juergen Goldschmidt, PhD

Andreas Heimdal, PhD

Sue Phillip, RCS



# Performing Tissue Synchronization Studies – Overview

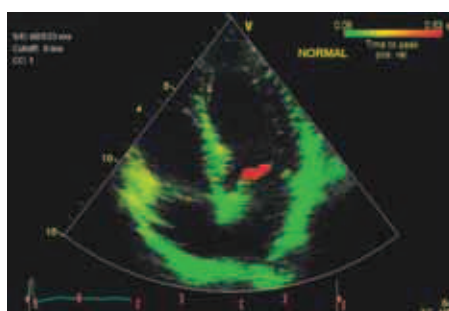
Tissue Synchronization Imaging (TSI) is a parametric imaging tool based on Tissue Velocity Imaging that provides clinicians with additional image enhancement for assessing delayed cardiac wall motion.

The TSI parametric image analyses the tissue velocity signals within the image to determine the peak velocities within a specified portion of the cardiac cycle. Since these peaks will occur in relation to overall motion, delayed wall motion will produce a delayed peak velocity.

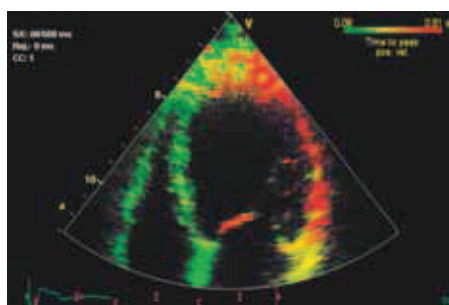
The amount of delay within the defined area of the cardiac cycle is used to assign a map or color to that location in the image. With TSI, the color represents the amount of tissue motion delay rather than the absolute value of the tissue velocity. When this technique is applied in real time across the 2D image, the variation in color provides both a qualitative and quantitative representation of wall motion delay allowing a trained physician to readily identify and evaluate asynchronous wall motion.

GE continues to invest in providing clinical tools for the diagnosis and treatment of heart failure by taking TSI to the next level with multi-dimensional imaging. It allows the user to acquire three planes simultaneously from the same cardiac cycle. This prevents any differences seen between the heart cycle lengths between the planes. It gives the user the ability to generate a bulls-eye display along with a 4D model with quantitative measurements and surface mapping so that you can better communicate cardiac dyssynchrony to Electrophysiologists and referring physicians.

Both images (below) are provided with a color scale relating the map color to the amount of delay in seconds (top right). An ECG trace (along the bottom) shows the electrical activity of the heart with markers to indicate the segment of the cardiac cycle being processed by TSI, as well as a cursor showing the location in the cardiac cycle of the displayed image. These images are normally viewed with real-time acquisition.



A normal cardiac cycle with an easily recognizable ECG and synchronous wall motion. The entire left ventricle is uniformly green in color.



Wall motion delay (asynchrony) as indicated by the red color segment in the lateral wall.

## Obtaining an Image

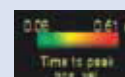For both 2D and multi-plane TSI (multi-plane requires the 3V probe):

- Use the default or your own customized Cardiac Preset.
- To enter the TSI mode, press TVI then press TSI.
- For single image: The common imaging planes acquired for TSI analysis are the apical 4, 2 and long axis views.
- For multi-dimension TSI - Select the 3V probe. While acquiring an apical 4C view, press the multi-dimension button, then press the tri-plane button.
- Acquire a full sector of the desired imaging plane. A full sector is preferred to simultaneously visualize and compare all the walls within the left ventricle. Accurate TSI analysis is achieved with frame rates around 100fps or higher.
- As with any Tissue Velocity Doppler imaging technique, care should be taken to keep the walls of interest aligned parallel with the transducer so that accurate velocities can be detected.
- To simplify TVI acquisition, TVI can be acquired in the background during any application (2D, stress echo or even contrast). Simply enter TVI mode, and then press the "TVI visible" button to hide the colors. This setting can be added to the User Preset. (Consult the User Manual for additional information.)

### TSI Color Coding

The time-to-peak positive velocity is colored continuously from green through yellow, and orange to red.

The exact start and end times for TSI are shown on the color bar.



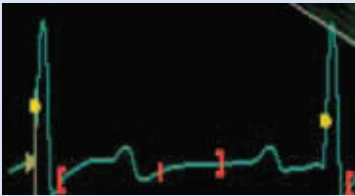
The TSI cutoff button assigns the same color for all regions that reach peak velocity earlier than the cutoff value.

Another color map that depicts blue and green can be selected for those who are color blind.

Note that the apex region does not allow a valid interpretation, as the Tissue Synchronization Imaging and measurement is based on tissue velocity information.

## Optimizing Controls

- Optimize 2D gain for a clean chamber that is free of noise. Automatic Tissue Optimization (ATO) can be utilized for this by simply depressing the gain button.
- An ECG trace, free of noise and with a consistent heart rate, should be used.
- Acquire one or more full heart cycles into cine loop.
- Typically, TSI start and end times do not need to be manually adjusted. The default settings are recommended.  
\*Please refer to the Advanced TSI White Paper for instructions on how to modify the TSI start/end time.



When TSI is activated, yellow QRS-markers will appear on the ECG trace. Make sure there is a yellow circle on each QRS complex at the point of the steepest rising slope.

\* Please refer to user manual for instructions on how to change the QR markers.

## Image Interpretation

Select TSI mode. Freeze 2D and scroll to the TSI end time. The image is colored according to the time-to-positive peak systolic velocity.

- Regions reaching peak velocity early in systole are marked in green.
- Regions reaching peak velocity late in systole or in diastole are marked in red.
- To add a level of quantification, the exact time-to-peak velocity for each point in the image can be easily measured.
- Freeze the loop in a late diastolic frame. Vivid 7 Dimension platform freezes at TSI end time.

### Early



### Late



#### Synchrony

- Regions reaching peak velocity at the same time
- Regions with the same color

#### Asynchrony

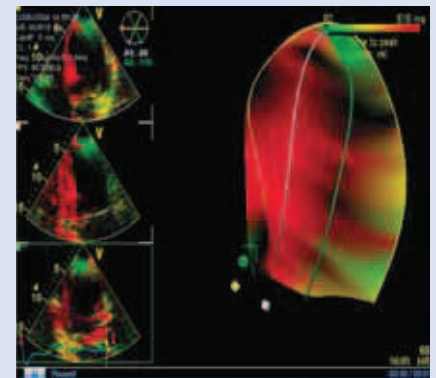
- Regions reaching peak velocity at different times
- Regions with different colors

## TSI Surface Map

The TSI surface map is a qualitative tool for identifying the extent and location of asynchrony in the left heart.

Quick Steps:

- Display a tri-plane TSI image. Press measure, enter TSI surface mapping.
- Starting at LV annulus on the left side of the A4C view, click at least five points along the walls around the LV (in middle of tissue), end on right side by double clicking.
- Repeat process for A2C and ALAX views.
- After completing all three traces, use trackball and scroll to End Systole. Repeat the process on all three views.
- To display-press Layout, press Show Scan Planes. Click on model with cursor and rotate around to reposition surface map.
- Store the image loop before exiting.



Tip: To generate a more accurate TSI Surface Map, draw the LV shape in the middle of the tissue rather than on the endocardial edge.

**If you would like to generate quantitative data from the TSI image, please refer to the Advance TSI Quantitative Analysis White Paper for information on the following:**

- How to perform time-to-peak measurements
- TSI bulls-eye report
- Asynchrony indexes
- TSI trace
- How to modify TSI start and end times

## Case Study

Breithardt, OA, Dept. of Cardiology,  
Univ.-Hospital Aachen, Germany

A 74-year-old male was diagnosed with dilated cardio-myopathy of non-ischemic origin two years ago. The patient remained stable on an optimized pharmacological therapy until recently, when he experienced progressive dyspnea. He was admitted to our hospital with acutely decompensated heart failure and pulmonary edema. Electrocardiographic QRS width on admission was 160 ms, with a left-bundle branch block morphology. After recompensation on I.V. diuretics, the QRS width became narrower again and was measured at 140 ms. Routine echocardiography showed severely reduced left ventricular systolic function, with an ejection fraction of less than 20% and severe mitral regurgitation. The echocardiographer noted an asynchronous contraction pattern and documented the degree of asynchrony with TSI (Figure 1). An indication for implantation of a biventricular pacemaker was made.

The left ventricular lead was implanted transvenously into an infero-lateral epicardial vein through the coronary sinus. After implantation, the atrioventricular delay was programmed to a standard value of 120 ms, with simultaneous biventricular pacing (no interventricular delay, VV = 0 ms). To confirm the resynchronization effect, another TSI exam was performed one month after the implant, which showed persistent

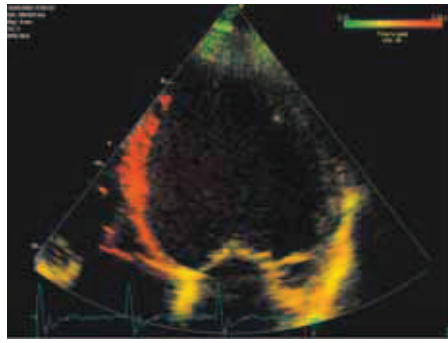


Figure 1

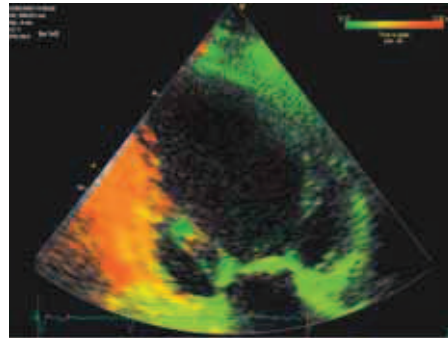


Figure 2

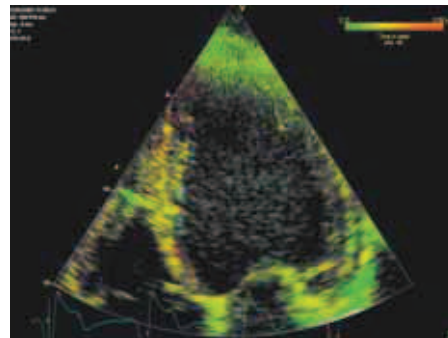


Figure 3

asynchrony with delayed motion of the septum and the inferior wall (Figure 2).

To achieve synchronous motion, it was necessary to shorten the atrioventricular delay to 100 ms, and to introduce an intraventricular delay with additional left-ventricular pre-excitation of 20 ms (VV = -20 ms). Under these settings, TSI demonstrated nearly simultaneous motion in all walls (Figure 3). Three months after reoptimization, the patient reported a marked improvement in symptoms and quality of life. The six-minute walking distance improved from 345 meters before implantation to 480 meters four months later.

For more information on Tissue Synchronization Imaging (TSI), visit [www.gehealthcare.com](http://www.gehealthcare.com)

#### List of TSI References:

- Bax JJ, Abraham T, Barold S, Breithardt OA, Fung JWH, Garrigue S, Gorcsan J 3rd, Hayes DL, Kass DA, Knuuti J, Leclercq C, Linde C, Mark DB, Monaghan MJ, Nihoyannopoulos P, Schalij MJ, Stellbrink C, Yu CM. Cardiac Resynchronization Therapy - Part 1 - Issues Before Device Implantation. *J Am Coll Cardiol.* 2005 Dec 20; 46(12):2153-67.
- Dohi K, Suffoletto M, Ganz L, Zenati M, Gorcsan J 3rd. Utility of echocardiographic tissue synchronization imaging to redirect left ventricular lead placement for improved cardiac resynchronization therapy. *Pacing Clin Electrophysiol.* 2005 May;28(5):461-5.
- Dohi K, Suffoletto M, Murali S, Bazaz R, Gorcsan J. Benefit of cardiac resynchronization therapy to a patient with a narrow QRS complex and ventricular dyssynchrony identified by tissue synchronization imaging. *Eur J Echocardiogr.* 2005 Dec;6(6):455-60.
- Gorcsan J 3rd, Kanzaki H, Bazaz R, Dohi K, Schwartzman D. Usefulness of echocardiographic tissue synchronization imaging to predict acute response to cardiac resynchronization therapy. *Am J Cardiol.* 2004 May 1;93(9):1178-81.
- Lind B, Nowak J, Dorph J, van der Linden J, Brodin LA. Analysis of temporal requirements for myocardial tissue velocity imaging. *Eur J Echocardiogr.* 2002 Sep; 3(3):214-9.
- Yu CM, Zhang Q, Fung JW. Images in cardiovascular medicine. Visualization of regional left ventricular mechanical delay by tissue synchronization imaging in heart failure patients with wide and narrow QRS complexes undergoing cardiac resynchronization therapy. *Circulation.* 2005 Aug 16;112(17):e93-5.

GE Healthcare  
9900 Innovation Drive  
Wauwatosa, WI 53226  
U.S.A.

[www.gehealthcare.com](http://www.gehealthcare.com)



© 2006 General Electric Company - All rights reserved.  
GE Healthcare, a division of General Electric Company

General Electric Company reserves the right to make changes in specifications and features shown herein, or discontinue the product described at any time without notice or obligation. Contact your GE representative for the most current information.

GE, GE Monogram, Vivid™ and EchoPAC™ are trademarks of General Electric Company.